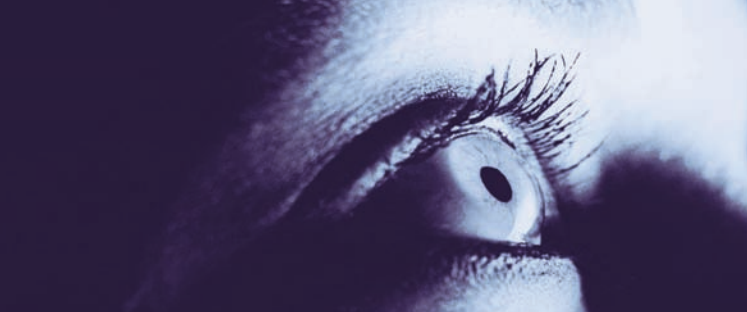



# University of Rochester Eye Institute Research Update THE OCULAR SURFACE AND TEAR FILM

by James V. Aquavella, MD, Geun-Young Yoon, PhD, James Zavislan, PhD; with Jennifer Anolik, MD, PhD, Thomas G. Brown, PhD, Steven Feldon, MD, Doreen Francis, William Gensheimer, Benjamin Hammond, MD, Krystal Huxlin, PhD, Shizuka Koh, MD, PhD, Ranjini Kottaiyan, OD, Kyesung Lee, PhD, Richard Libby, PhD, Richard Phipps, PhD, Jannick Rolland, PhD, Amit Sangave, Karin Skrine, Cynthia Tung, David R. Williams, PhD

## Background and Significance

Wolff<sup>3,4</sup> provided a description of the tear film as a three-layered structure comprising a lipid (oil) layer, an aqueous (water) layer and a mucus layer over the corneal epithelium as shown in Fig. 1. The lipid layer is the most outer surface providing a smooth tear surface and retarding the rate of tear evaporation from the cornea. The aqueous layer is comprised of water promoting spreading of the tear film. The inner-most layer of the tear film serves as an anchor for the tear film and helps it adhere to the eye. The tear film creates a smooth surface for light to pass through the eye, nourishes the front of the eye, and provides protection from infection.

Smooth precorneal tear film formed after blinking is important not only to protect the ocular anterior surface but also to maintain visual function. If the precorneal tear film is not intact, its break-up may cause a rough and irregular surface of the cornea and have an adverse influence on the ocular system. Dysfunction of the tear film may result in dry eye disease. The condition is often associated with ocular discomfort, including symptoms of dryness, irritation, and burning. From the optical viewpoint, the unstable tear film and resulting in non-uniform optical surface degrade quality of images formed on the retina. This in turn affects quality of vision significantly in dry eye patients.<sup>5,6</sup> As revised worldwide criteria for dry eye are being considered,<sup>7</sup> much attention has been paid to understand dry eye. While qualitative and quantitative tear film dysfunction adversely affects many of the US population (as many as 60 million) especially elderly individuals (5 million over the age of 50 and as many as 80% of individuals over 80 years of age), our current under-

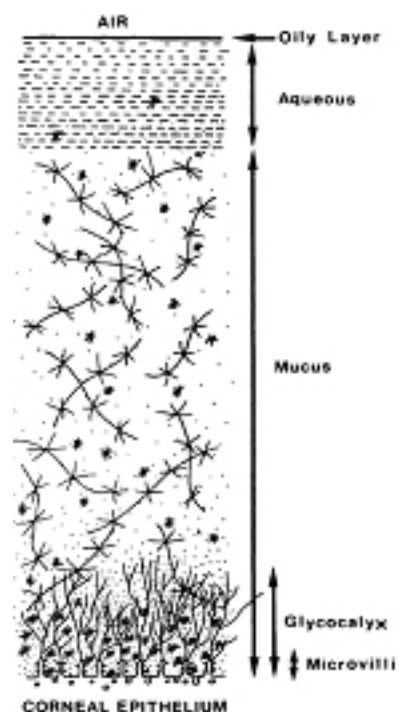


Figure 1. Schematic diagram of tear film structure



standing of tear film structure and its optical properties is elementary. In clinical examination of dry eye patients, there are various situations that require precise understanding of the spatial relationships and dimensions of tear film. Objective, quantitative evaluation of visual symptoms associated with dry eye is also necessary to understand causation. Because tear film effects alternations in tear cycle and the static image taken may not represent tear film states between blinks, it is also important to have the ability to monitor dynamic changes of the tear film. Moreover, it is critical to observe the natural status of tear film and detect its changes without causing the disturbance to the tear film. Previous reports have limitations in the results due to the fact that forced repeated blinking, topical anesthesia<sup>8,9,10</sup> or an artificial eye drop was used. To this end, we will have developed new methods to overcome these limitations by means of non-invasive, simultaneous and sequential measurements of the tear film.

With the exponential increase of computer usage in the office, dry eye related to visual terminal (VDT) use has been a major health problem.<sup>11</sup> In a clinical population, there are numerous borderline cases that fall between evaporative dry eyes and normal eyes, in which tear film instability and dry eye symptoms are found without ocular surface damage and tear deficiency. Even in clinically normal subjects, those "at risk of developing dry eye" were identified with unstable variations in sequential post blink changes in optical quality of the eye.<sup>9</sup> Because tear film instability may predispose to dry eye in response to ocular surface stress in borderline cases of evaporative dry eye or in "at risk developing dry eye" cases, it is extremely important to have more reliable and objective criteria for early diagnosis of dry eye and perhaps more importantly for adequate treatment choice among numerous options.

Therefore, we strive to understand quality and thickness of the tear film and its optical properties as it changes dynamically in normal individuals and in those with dry eye symptoms in normal and adverse environmental conditions. We developed three different imaging modalities that allow for objective and noninvasive examinations of the tear film and make it possible to investigate the temporal changes of tear film characteristics in real-time.

### Objective multimodal ocular tear-film assessment system.

Our different imaging technologies, high resolution wavefront sensor, optical coherence tomography (OCT) and ellipsometer. Each imaging modality provides important information to characterize the tear film. Wavefront sensor measures changes in optical quality of the eye caused by the tear film and their impact on quality of vision, and makes it possible to objectively estimate tear film break-up time which is one of the most important measures of dry eye symptoms. OCT is capable of measuring tear film thickness over the cornea and at the upper-lid and lower-lid tear menisci. This capability is essential for research of a tear dynamics model including tear secretion, tear collection, tear evaporation and tear drainage. An ellipsometer that measures polarization properties of light has the unique capability to measure a very thin film and its refractive index. We use the ellipsometer to measure thickness of the lipid layer (<100 nm) of the tear film and quality (refractive index) of the tear film. We use infrared wavelengths of light source for these instruments so that light sources will not induce reflex tearing or blinks due to bright stimulation.

## Advanced tear film imaging technologies

Ocular wavefront sensor<sup>12,13</sup>: The front surface of the tear film has the most impact on optical quality of the eye. This is due to the largest difference in refractive index between air and the tear. Any non-uniformity in the tear film thickness that induces optical defects, called aberration, causes significant degradation of optical quality of the eye. Measuring the aberration provides two-dimensional spatial information on how a tear surface profile changes in time. We have developed a high resolution infrared Shack-Hartmann sensor that is capable of measuring high spatial frequency structures such as tear film breakups. Figure 2 shows an example of a tear film break pattern measured with the wavefront sensor. This sensor is currently modified to have a higher resolution for both clinical studies and further scientific development of dry research.




Figure 2. Tear film pattern break-up pattern (left) and measured wavefront aberration (right)

Optical coherence tomography (OCT)<sup>14,15</sup>: OCT is a non-invasive, high-resolution imaging technique based on low-coherence interferometry and provides in vivo cross-sectional images of biological tissues. Its principle is the same as ultrasound imaging with only one difference. OCT uses light waves instead of sound waves. Light waves are sent into the sample and the time delay is measured using interference of the sample and reference beams. OCT can provide high resolution images (2-10 $\mu$ m) depending on center wavelength and bandwidth of light source. We use OCT to image the anterior segment of the eye especially around tear boundaries. Figure 3 shows a cross sectional image including cornea and both lower and upper tear menisci capture with our OCT with a 10 $\mu$ m axial resolution. We upgraded the current OCT to have a 1 $\mu$ m resolution so that tear thickness (several microns) over the cornea can be imaged.

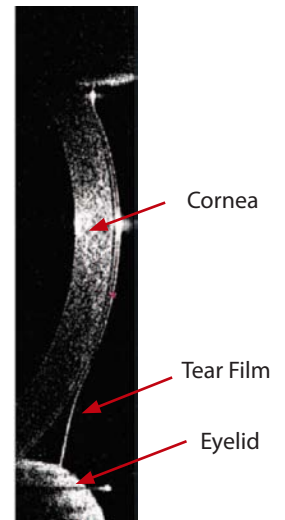


Figure 3. OCT image of cornea and tear menisci

Ellipsometer<sup>16</sup>: Ellipsometry is a method measuring polarization states of light that are determined by thickness and refractive index of a layer.<sup>16</sup> Although the lateral resolution of an optical imaging system is typically limited by diffraction, ellipsometry can achieve a very high resolution (nanometer order) axial resolution of layered materials by sensing the polarization state of light reflected off the layers. We use this technique to measure thickness and refractive index of the lipid layer of the tear film over a course between blinks and tear break up by measuring the polarization state of a two-wavelength ellipsometer. Although a stand-alone instrument at this time, the ellipsometer has a measurement geometry that allows the instrument to be integrated with the wavefront sensor and OCT to form a multi-modal tear film metrology system (Figure 4.)

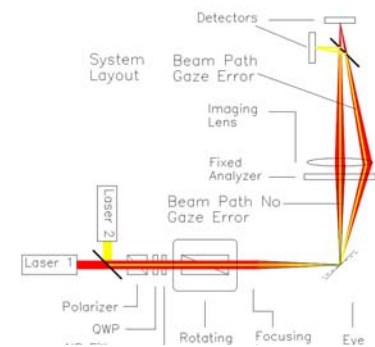


Figure 4. Schematic of ellipsometer

We recruit dry eye patients with insufficient tear production and normal subjects as a control group. In a clinical setting, three imaging systems are used to obtain the following data from both patient and control groups: (1) film break-up time, (2) dynamics in tear volume at tear menisci, (3) thickness and refractive index of the lipid layer. We perform statistical analyses on the data set to investigate significant differences between the

groups, and collect multiple 2 dimensional cross sectional OCT images in real time to quantify the total tear volume in normal and dry eye patients.

The same methodology deployed in our adverse environmental chamber to determine efficiency range is used to evaluate the efficacy of therapeutic eye drops. This capability will be highly attractive to the eye care industry by reducing the time frame for clinical trials and expedite the release of new therapeutic modalities. The ability to combine objective analysis and environmental challenges constitutes a powerful tool to enhance our understanding of the physiopathology of the ocular surface, and to predict efficacy of proposed topical lubricants and tear film enhancement agents.

## Literature cited

1. 2007 Report of the International Dry Eye WorkShop, *Ocul. Surf.*, 5 (2), 65-206 (2007).
2. Survey of Preferred Tests for Diagnosis of the Tear Film and Dry Eye, *Cornea*, 19 (4), 483-486 (2000).
3. Wolff, E., The muco-cutaneous junction of the lid margin and the distribution of the tear fluid. *Trans. Ophthalmol. Soc. UK* 66, 291-308 (1946).
4. Wolff, E., *The Anatomy of the Eye and Orbit*, fourth ed., H.K. Lewis and Co, London, pp. 49 (1954).
5. Goto E, Yagi Y, Matsumoto Y, Tsubota K. Impaired functional visual acuity of dry eye patients. *Am J Ophthalmol.* 2002;133:181-186.
6. Ishida R, Kojima T, Dogru M, et al. The application of a new continuous functional visual acuity measurement system in dry eye syndromes. *Am J Ophthalmol.* 2005;139:253-258.
7. Dogru M, Stern ME, Smith JA, Foulks GN, Lemp MA, Tsubota K. Changing trends in the definition and diagnosis of dry eyes. *Am J Ophthalmol.* 2005;140:507-508.
8. Montes-Mico R, Alio JL, Charman WN. Dynamic changes in the tear film in dry eyes. *Invest Ophthalmol Vis Sci.* 2005;46:1615-1619.
9. Koh S, Maeda N, Hirohara Y, et al. Serial measurements of higher-order aberrations after blinking in normal subjects. *Invest Ophthalmol Vis Sci.* 2006;47:3318-3324.
10. Koh S, Maeda N, Hirohara Y, et al. Serial measurements of higher-order aberrations in patients with dry eye. *Invest Ophthalmol Vis Sci* (in press)
11. Tsubota K, Nakamori K. Dry eyes and video display terminals. *N Engl J Med* 1993;328:584. Koh S, Maeda N, Hori Y, et al. Effects of suppression of blinking on quality of vision in borderline cases of evaporative dry eye. *Cornea* (in press)
12. Liang J, Grimm B, Goelz S, Bille J. Objective measurement of the wave aberrations of the human eye using a Hartmann-Shack wavefront sensor. *Journal of the Optical Society of America A* 1994;11:1949-1957.
13. Li KY, Yoon G. Changes in aberrations and retinal image quality due to tear film dynamics. *Optics Express.* 2006;14:12552-12559.
14. Radhakrishnan S, Rollins AM, Roth JE, et al. Real-time optical coherence tomography of the anterior segment at 1310 nm. *Arch Ophthalmol.* 2001;119:1179-1185.
15. Wang J, Aquavella J, Palakuru J, Chung S, Feng C. Relationships between central tear film thickness and tear menisci of the upper and lower eyelids. *Invest Ophthalmol Vis Sci.* 2006;47:4349-4355.
16. R. M. A. Azzam and N. M. Bashara, *Ellipsometry and Polarized Light*, Elsevier Science Pub Co (1987).